

44 - Pharyngitis Syndromes and Group A Strep

Speaker: Karen C. Bloch, MD

IDBR
INFECTIOUS DISEASE BOARD REVIEW
AUGUST 20-24
2022

Pharyngitis Syndromes and Group A Strep

Karen C. Bloch, MD, MPH, FIDSA, FACP
Professor, Division of Infectious Diseases
Vanderbilt University Medical Center

7/17/2022

IDBR
INFECTIOUS DISEASE BOARD REVIEW
AUGUST 20-24
2022

Disclosures of Financial Relationships with Relevant Commercial Interests

- None
- But, Special Thanks to Dr. Bennett Lorber!



Think Like a Realtor

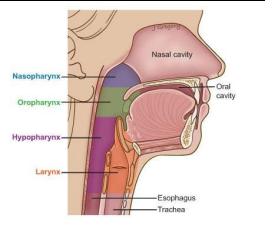


Think Like A Realtor



Location
Location
Location

Pharyngitis



- Small square footage
- Micro-neighborhoods
- Regional differences

Case 1 **PREVIEW QUESTION**


38yo female with 1 day of sore throat and fever.
Childhood history of anaphylaxis to penicillin.

Physical exam

- T=102.3
- HEENT-tonsillar purulence
- Neck-Tender bilateral anterior LAN

Labs:

- Rapid strep antigen test **negative**



44 - Pharyngitis Syndromes and Group A Strep

Speaker: Karen C. Bloch, MD


Question 1 2022 PREVIEW QUESTION

What is the most appropriate antimicrobial treatment?

- A. Cephalexin
- B. None
- C. Doxycycline
- D. Clindamycin
- E. Levofloxacin


Group A streptococcus

- AKA *Streptococcus pyogenes*
- 5-15% sore throats in adults
- Usually *self-limited* infection (even untreated)




Differentiating Pharyngitis

GAS



Viral pharyngitis



vs

Differentiating Pharyngitis

GAS

- Sudden onset
- Fever
- Lymphadenopathy
- Exposure to contact with streptococcal pharyngitis

Viral pharyngitis

- The 3 C's
 - Conjunctivitis
 - Coryza
 - Cough
- Other symptoms
 - Diarrhea
 - Ulcerative stomatitis
 - Hoarseness

How Specific are Clinical Findings?


- Modified CENTOR score
- Can't cough
- Exudate
- Nodes
- Temperature
- OR age <15 yr (+1) or >44 years (-1)

Points	Strep probability
0 or 1	< 10%
2	11 -17%
3	28 -35%
4 or 5	35-50%


IDSA guidelines recommend antibiotics only following a RADT positive testing.

Streptococcal Clues

• Palatal petechia



• Scarletina



44 - Pharyngitis Syndromes and Group A Strep

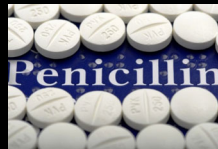Speaker: Karen C. Bloch, MD

Laboratory Diagnosis

- Adults:
 - RADT screen, if negative, culture optional
- ASO titer or Anti-DNAse B antibodies
 - helpful in diagnosis of rheumatic fever and post-streptococcal glomerulonephritis, but **not** for strep pharyngitis.

Treatment for GAS Pharyngitis

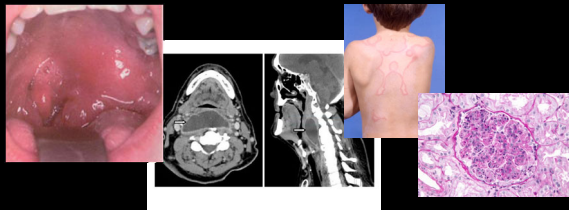
- First line:
 - Oral Penicillin or amoxicillin x 10 days



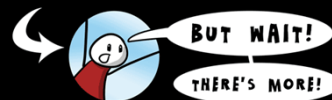- PCN Allergic:
 - cephalosporin, clindamycin, macrolides (+/-)
 - Not recommended: tetracyclines, sulfonamides, fluoroquinolones

Secondary Complications

- Infectious complications
- Immunologic complications



Pharyngitis and...

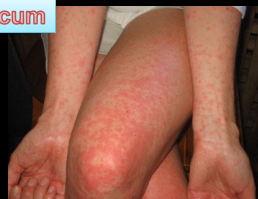

Pharyngitis & Rash

- Young adult with fever, sore throat, tonsillar exudate, scarletiform rash BUT...Negative RADT and culture

Arcanobacterium haemolyticum

- Gram positive rod
- Rash in >50%, mimics strep
- Rarely life-threatening sequelae



Pharyngitis & Rash

- Acute HIV
- Secondary syphilis

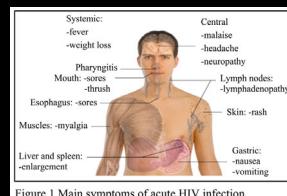
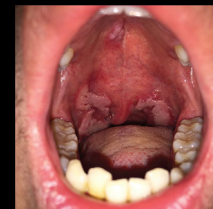

Figure 1 Main symptoms of acute HIV infection



44 - Pharyngitis Syndromes and Group A Strep

Speaker: Karen C. Bloch, MD

Pharyngitis after Receptive Oral Intercourse

Neisseria gonorrhoeae

- Highest risk MSM
- Diagnose by nucleic acid amplification test of pharyngeal swab

Herpes simplex virus

- HSV-2
- Usually with initial infection
- Tonsillar vesicles
- Labial or genital ulcers variably present

Pharyngitis & Conjunctivitis

- College freshman with sore throat, fever, and conjunctivitis.
- Roommate and 3 others in her dorm with similar syndrome

Adenovirus



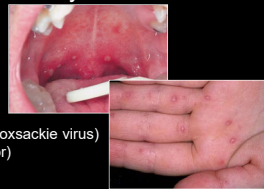
Epidemics in group living situations—barracks, dorms, camps, etc

Pharyngitis and Vesicles

- 35 yo man with sore throat, low grade fever, and lesions on palms & soles. His 3 yo son is sick with a similar illness.

Hand, Foot, and Mouth disease

- Caused by enteroviruses (most common Coxsackie virus)
- More common in kids (often serve as vector)



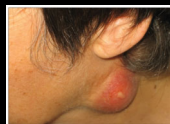Case 2

- A 62 yo man presents with 24hr of fever, chills, and odynophagia
- He works at a vineyard in Napa Valley, and last week participated in the grape harvest. He admits to sampling the grape must.
- His cat recently had kittens



Case 2

- PE:
Ill appearing,
T=102.4, HR=122, BP=97/52
left tonsil swollen and erythematous
Left suppurative lymph node tender to palpation



CMAJ 2014;186:E62

Question 2

What is the most likely cause of this patient's illness?

- A. Toxoplasmosis
- B. Bartonellosis (Cat Scratch Fever)
- C. Tularemia
- D. Epstein Barr virus
- E. Scrofula (mycobacterial lymphadenitis)

44 - Pharyngitis Syndromes and Group A Strep

Speaker: Karen C. Bloch, MD

Oropharyngeal Tularemia

- Uncommon in the US
- Transmission through ingestion (or rarely inhalation)
 - Inadequately cooked game
 - Contaminated water
 - Rodent contamination
- Exudative tonsillitis, **suppurative LAN**
- Treatment: streptomycin, doxycycline or quinolone

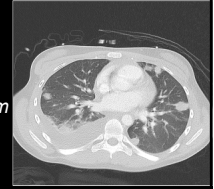


Pharyngitis and Chest Pain

- 20 yo college student with sore throat, fever and chills. Despite oral amoxicillin, develops new onset of cough and pleuritic CP; CT below

Lemierre syndrome

- Septic phlebitis of internal jugular vein
- Often follows GAS pharyngitis or mono (EBV)
- Classic cause is *Fusobacterium necrophorum*
- Causes septic pulmonary emboli

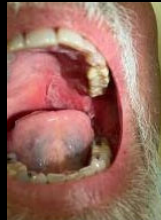

Pharyngitis & TNF-alpha inhibitors

- 69yo man on infliximab presents with 2 months of painful oral ulcer and 20 lb wt loss

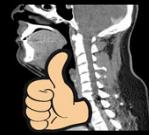Oropharyngeal Histoplasmosis

- Can mimic oral malignancy
- Denotes disseminated disease



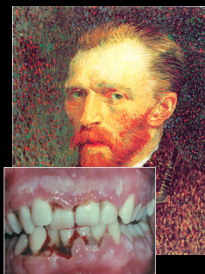Extra-Tonsillar Infections: 1

- Epiglottitis
 - Fever, sore throat
 - Hoarseness, drooling, muffled voice, stridor
 - Examine with care!
 - Lateral neck x-ray: Thumb sign
 - *H. influenzae* type B, pneumococcus



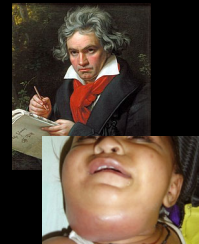Extra-Tonsillar Infections: 2

- Vincent Angina
 - AKA Trench mouth
 - AKA acute necrotizing ulcerative gingivitis
 - Bad breath (mixed anaerobes)
 - Painful
 - Sloughing of gingiva



Extra-Tonsillar Infections: 3

- Ludwig Angina
 - Cellulitis of floor of the mouth
 - Often starts with infected molar
 - Rapid spread with potential for airway obstruction
 - Fevers, chills, drooling, dysphagia, muffled voice, **woody induration of neck**
 - Mixed oral organisms



44 - Pharyngitis Syndromes and Group A Strep

Speaker: Karen C. Bloch, MD

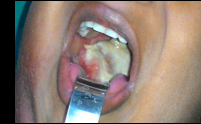Case 3

INFECTION DISEASE BOARD REVIEW 2022 PREVIEW QUESTION

- A 32-year-old woman is seen for a bad sore throat for 4 days
- Recently returned from her sister's wedding in Kazakhstan
- She c/o odynophagia, and a low-grade fever. Today, she noted a choking sensation, prompting medical evaluation.

INFECTION DISEASE BOARD REVIEW 2022 PREVIEW QUESTION

- T 100.2F; P 126; BP 118/74.
- HEENT: Submandibular swelling with gray exudate coating posterior pharynx. An S3 gallop is heard.



- EKG shows 1st degree AV nodal block, QT prolongation, and ST-T wave changes.

Question 3

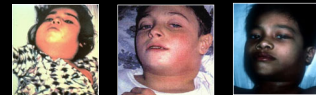INFECTION DISEASE BOARD REVIEW 2022 PREVIEW QUESTION

The most likely diagnosis is?

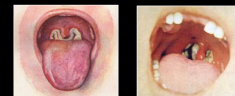- A. Streptococcal pharyngitis
- B. Kawasaki disease
- C. Vincent angina
- D. Diphtheria
- E. Candida

Buzz words and Visual Associations

Bull neck:

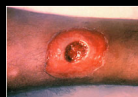

Grey pseudomembrane: extends onto palate or uvula; bleeds when scraped



Other clues

- Location, location, location
 - Almost unheard of in developed countries (vaccination)
 - Still an issue (high mortality) in developing world
- Sore throat and myocarditis (~25%).
- Sore throat and neuropathies (~5%).
- Sore throat and cutaneous ulcer



Noninfectious Mimics

- PFAPA (periodic fever, aphthous stomatitis, pharyngitis, and adenitis)
- Still's disease
- Lymphoma
- Kawasaki disease
- Behçet disease



44 - Pharyngitis Syndromes and Group A Strep

Speaker: Karen C. Bloch, MD

